Bronchoscopy

TSDA Boot Camp

September 12-15, 2019

Chapel Hill, NC

Bronchoscopy/Mediastinoscopy Faculty

- Carolyn Jones, MD, Course Leader
- Manjit Bains, MD
- Michael Jaklitsch, MD
- Joe Miller, MD
- Michael Mulligan, MD
- Roman Petrov, MD
- Joseph Wizorek, MD

Goals

- Laryngeal and Airway Anatomy
- Flexible Bronchoscopy
  - Basics
  - Indications/ Contraindications
- Rigid Bronchoscopy
  - Basics
  - Indications/ Contraindications

The Larynx

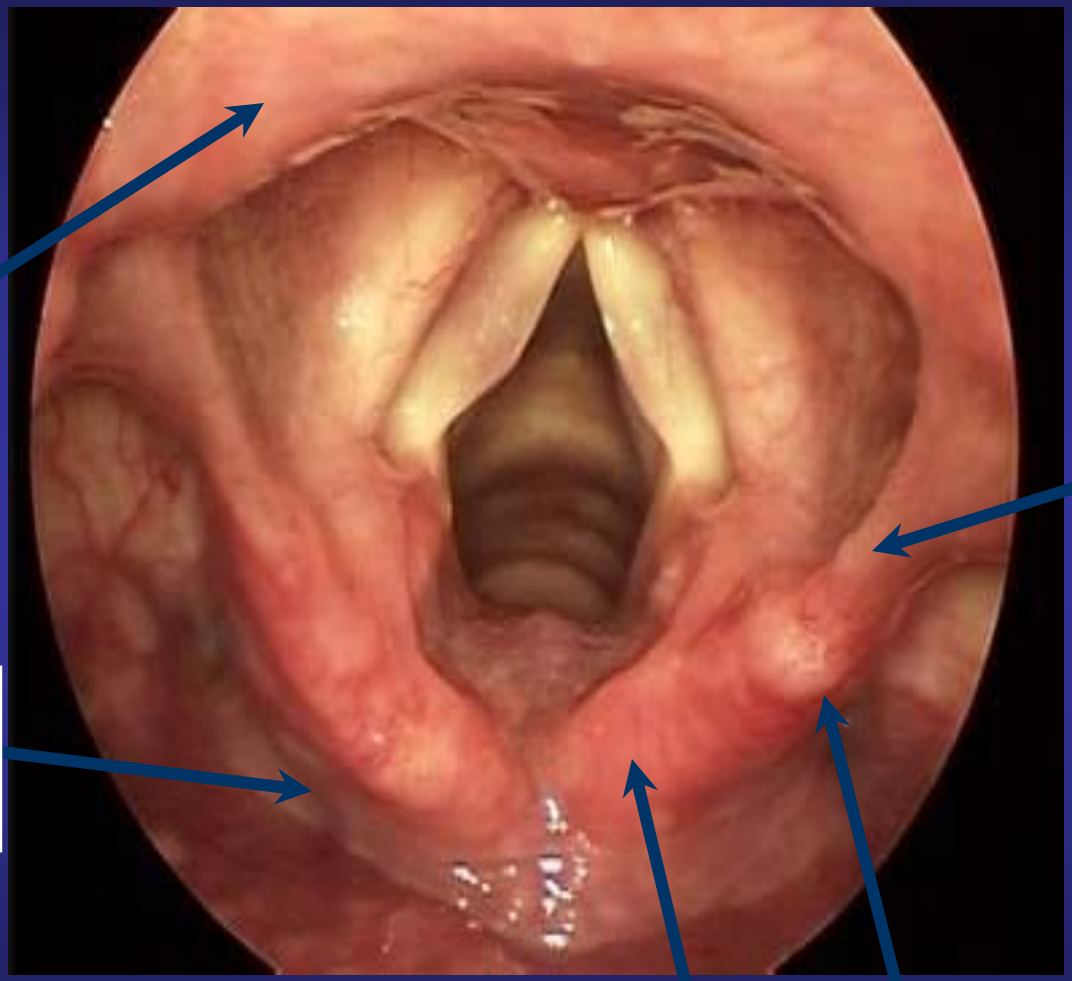

Epiglottis

Aryepiglottic fold

To the Esophagus

Cuneiform and corniculate cartilage

The Larynx: Anat**omy**

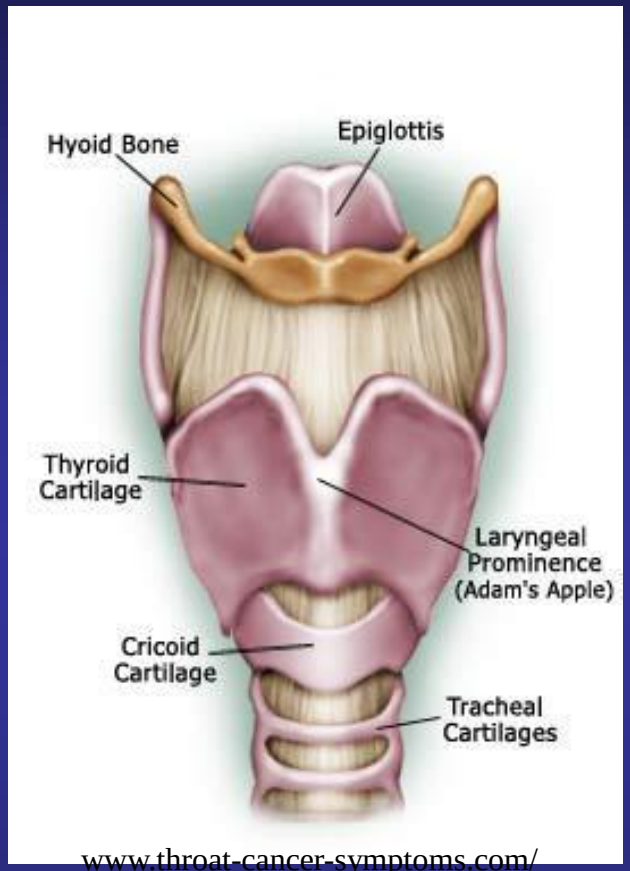

www.throat-cancer-symptoms.com/

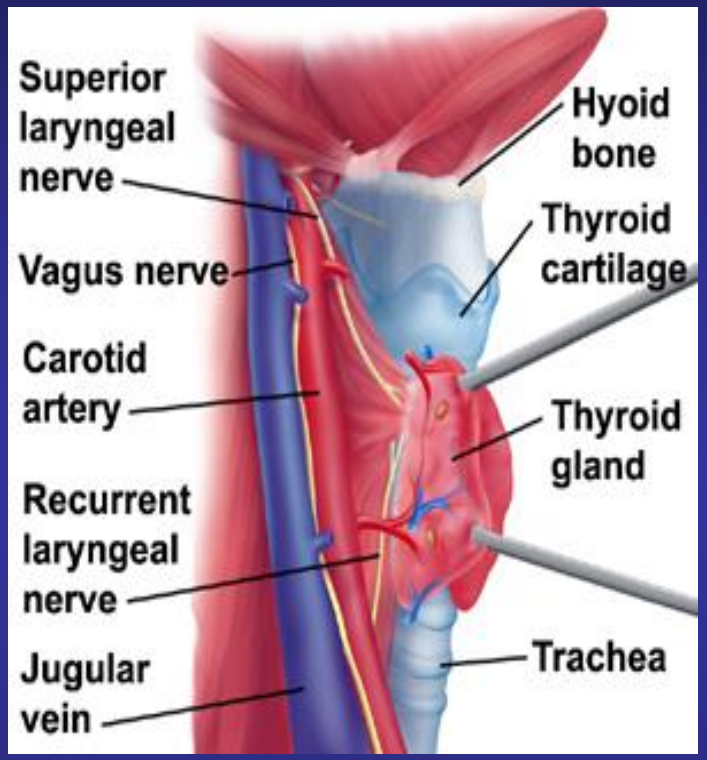

www.yoursurgery.com

- Structural rigidity provided by: The epiglottis, Thyroid cartilage and Cricoid cartilage

The Larynx II

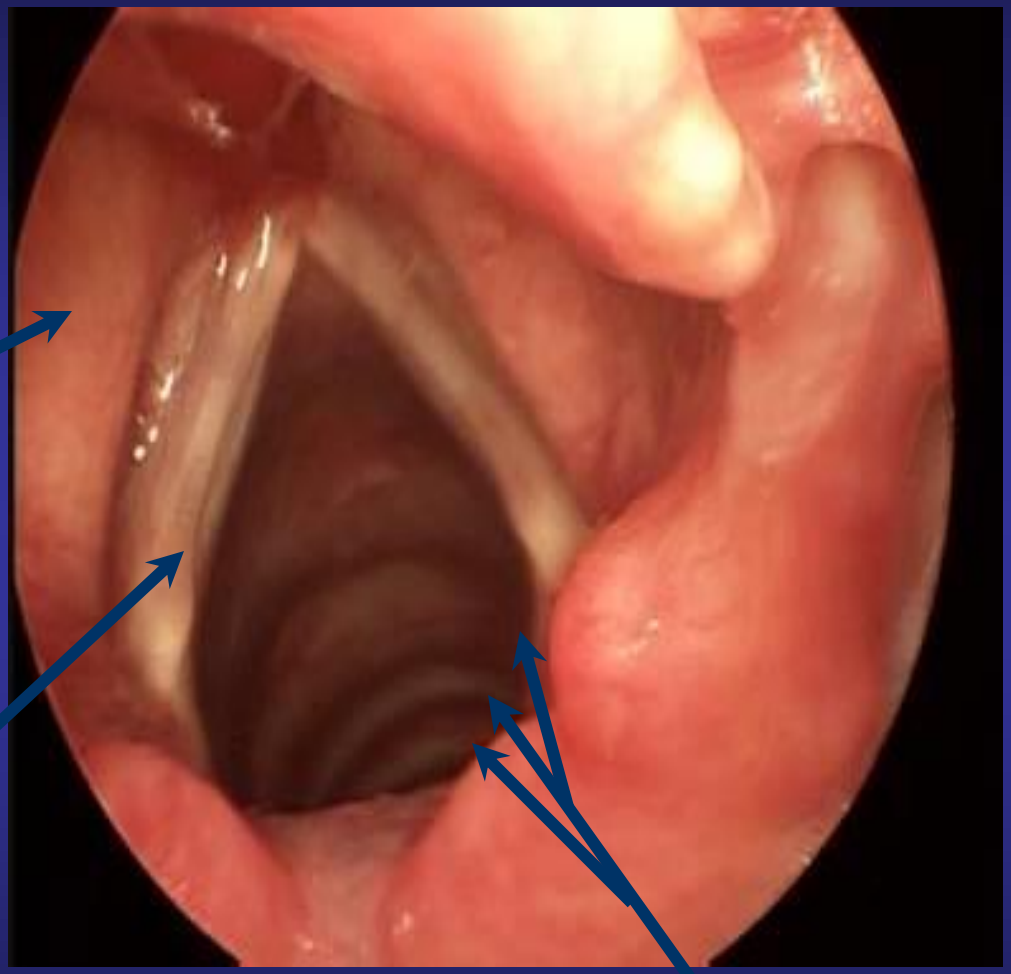

False Vocal Cords

True Vocal Cords

Tracheal Cartilaginous Rings

Epiglottis

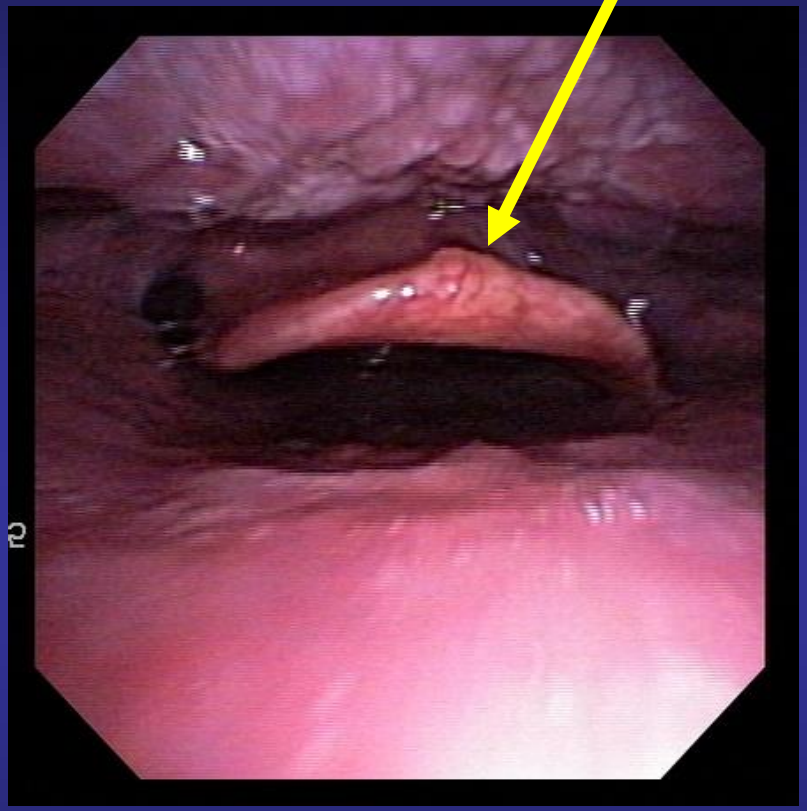

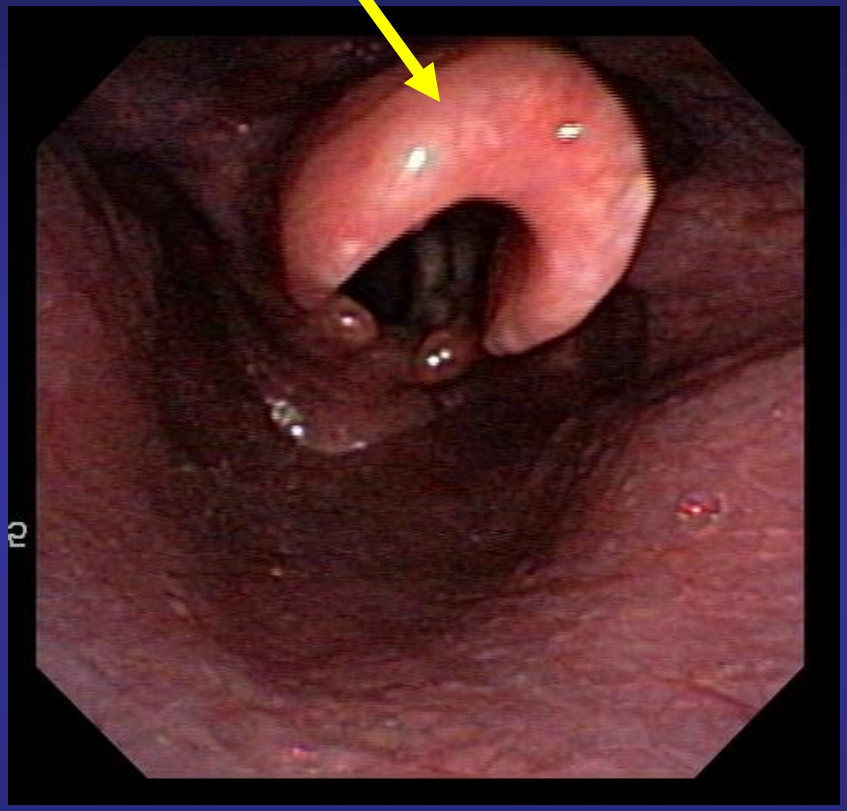

http://www.Bronchoscopy.org/Bronchatlas/htm. Accessed 6/11/2007

The Larynx

open for inspiration and closed for swallowing

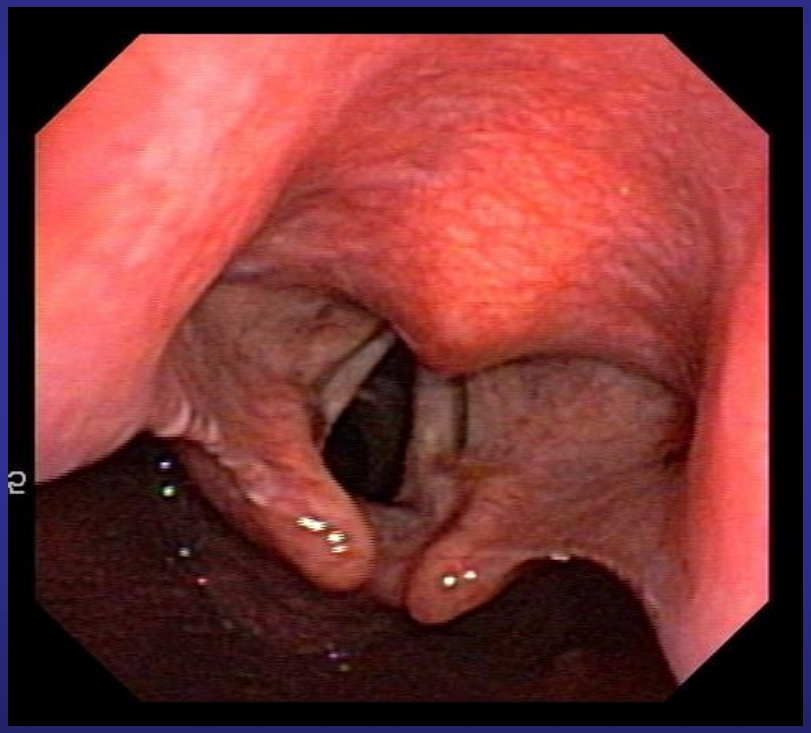

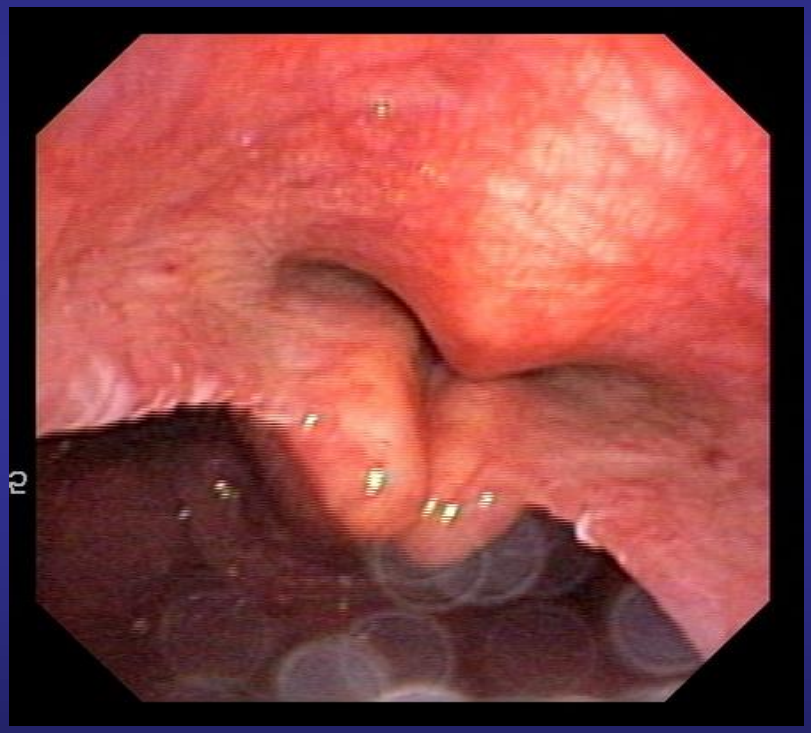

http://www.Bronchoscopy.org/Bronchatlas/htm. Accessed 6/11/2007

The Adult Trachea

- Length: 9-15 cm
- Internal diameter: 12-18 mm
- Outer diameter: 21-27 mm
- 18-22 cartilaginous rings
- Becomes intrathoracic at 6th cartilaginous ring

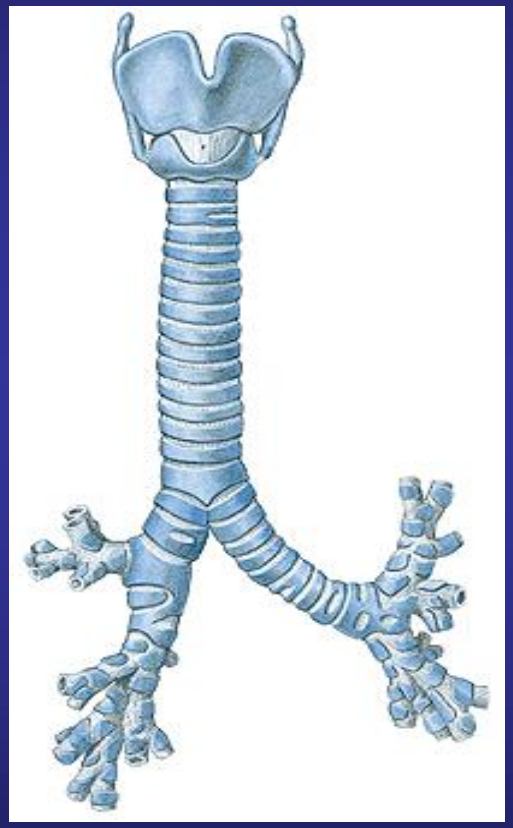

Tracheal dimensions – adult male

- Average cross-sectional area is 2.8 cm2

- Upper limits of normal Transverse diameter of 25 mm and AP diameter of 27 mm

- The lower limit of normal for both diameters is about 13 mm

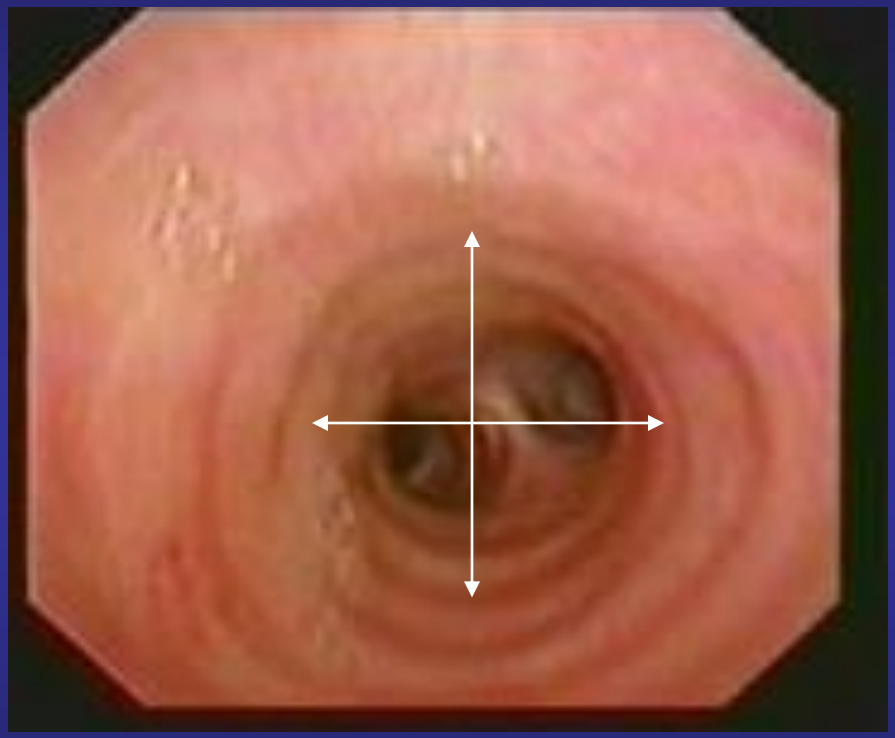

Tracheobronchial Anatomy

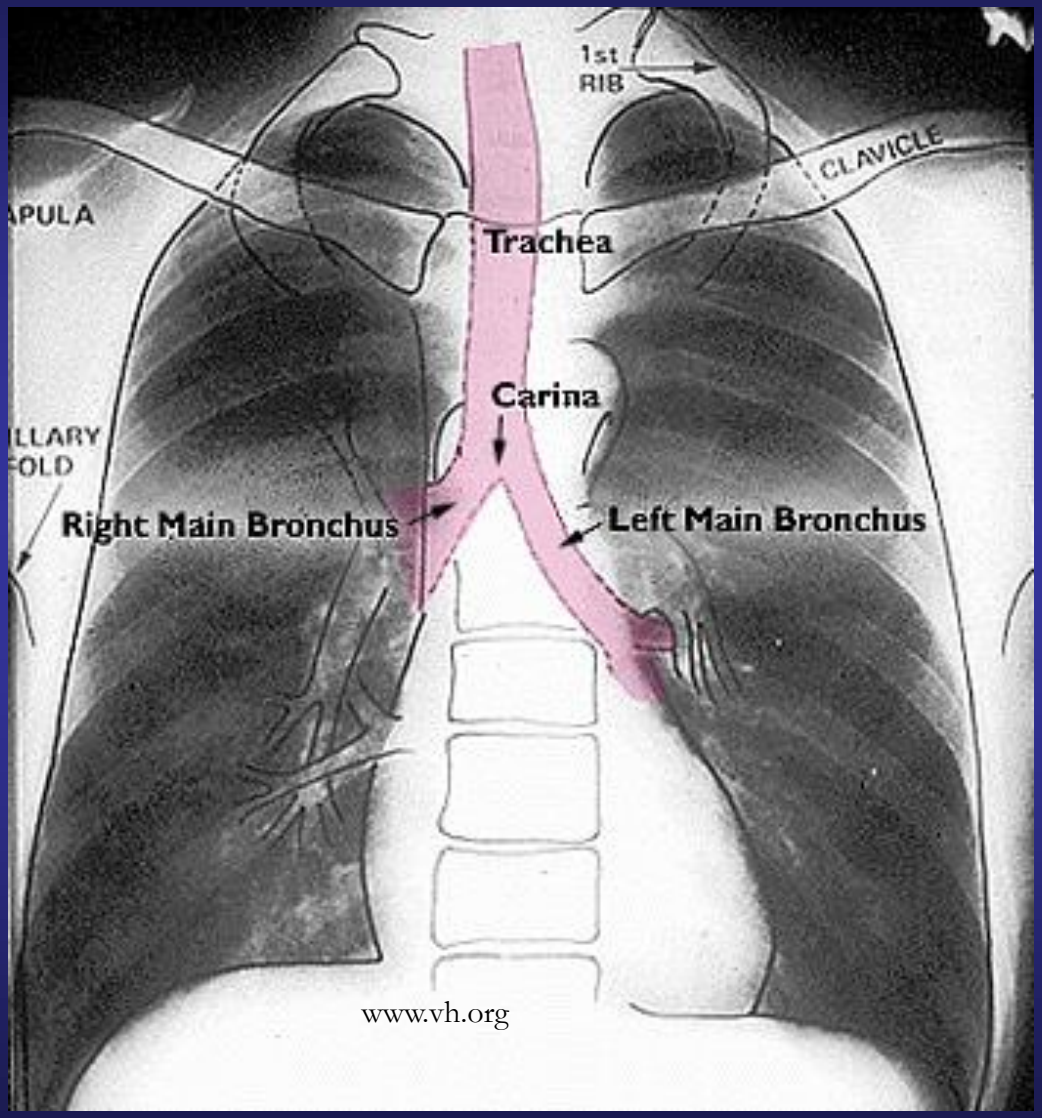

The Carina

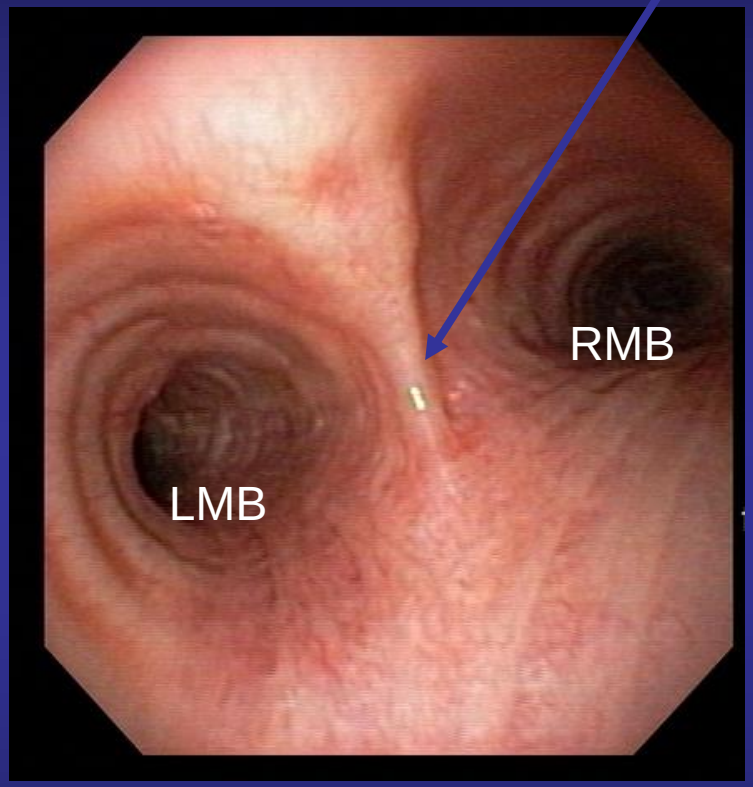

posterior

From front of patient

Lobar and Segmental Anatomy

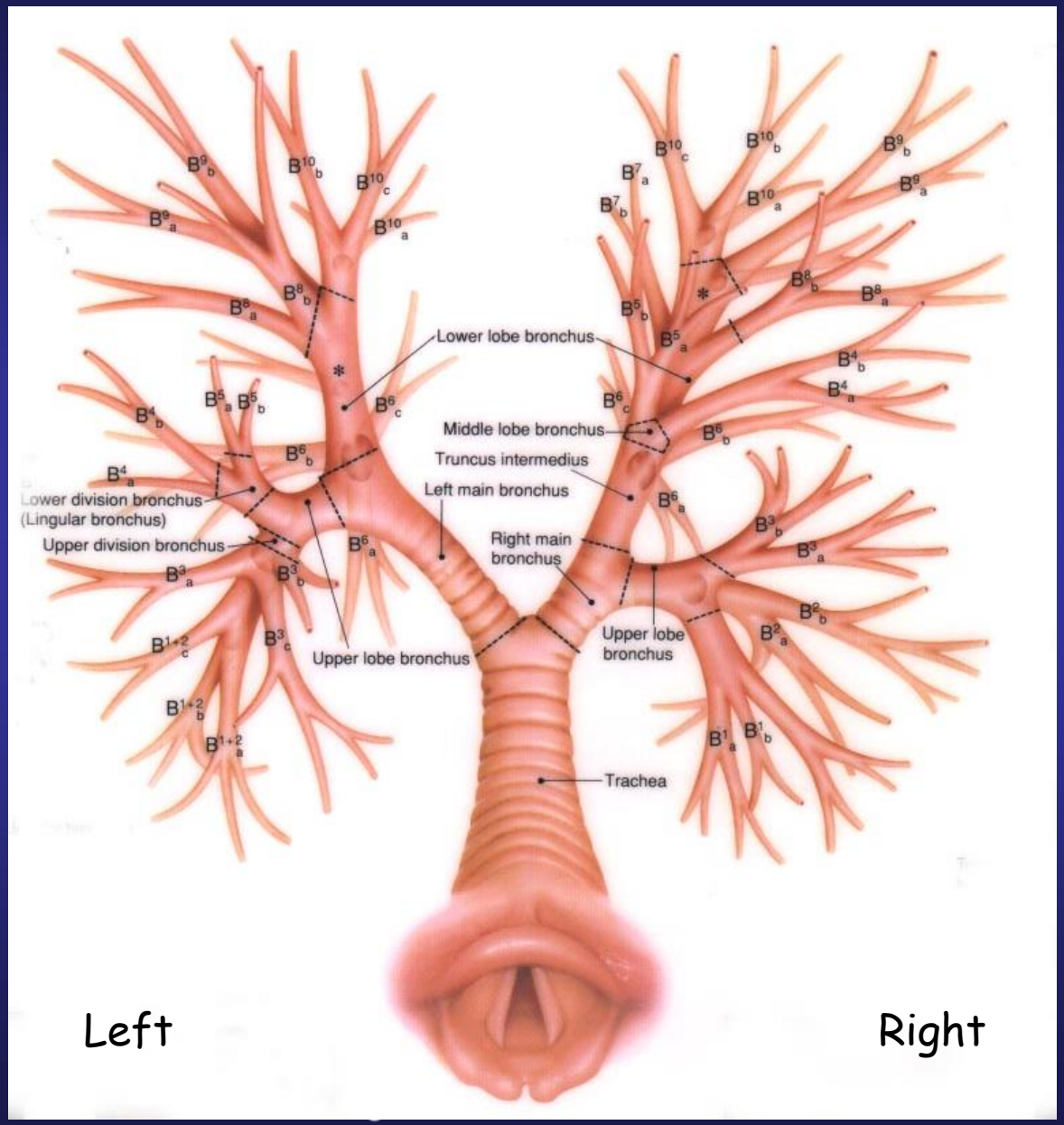

Right Bronchial Anatomy

- Right main bronchus
  - 2cm long, I.D. 10-16mm
    - Right upper lobe
    - Bronchus intermedius
      - Middle lobe
      - Lower lobe

The Right Bronchial Tree: Classification

JACKSON-HUBER	BOYDEN
Right Upper lobe	
Apical	B^1
Anterior	B^2
Posterior	B_3
Right middle lobe	
Lateral	B^4
Medial	B^5
Right lower lobe	
Superior	B^6
Medial basal	B^7
Anterior basal	B^8
Lateral basal	B^9
Posterior basal	B^{10}

Left bronchial anatomy

- Left main bronchus
  - 4-5cm long, slightly smaller than right (I.D. 8-14mm)
    - Left upper lobe and Lingula
    - Left lower lobe

Left Bronchial Tree- nomenclatures

JACKSON-HUBER	BOYDEN
Left upper lobe	
Upper division	
Apical-posterior	**$B^{1 \& 3}$**
Anterior	**B^{2}**
Lingular/division	
Superior	**B^{4}**
Inferior	**B^{5}**
Left lower lobe	
Superior	**B^{6}**
Anteromedial	**$B^{7\&8}$**
Lateral basal	**B^{9}**
Posterior basal	**B^{10}**

Flexible Bronchoscopy



Courtesy of Robert Garland RRT

How deep can you go?

Conducting Airways			Gas Exchange Airway		
Cartilagenous		Membranous	Terminal Respiratory Unit		
Trachea	Bronchi	Bronchioles	R. Bronchioles	A. Ducts	A. Sacs
No alveoli			Alveoli		
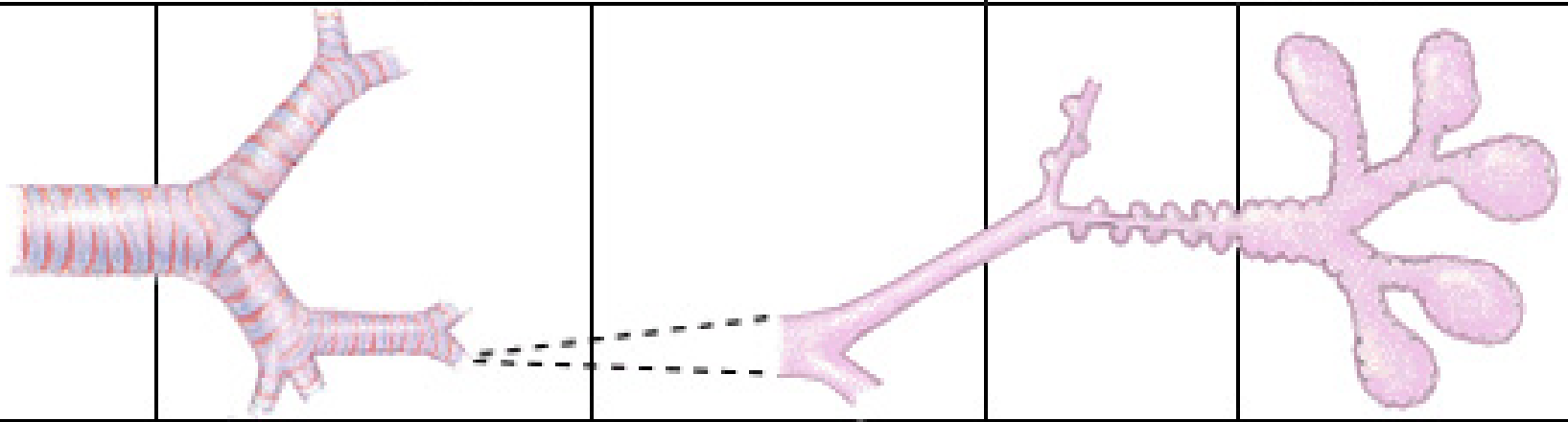					
Generation 0	1 2 → 10	11-13 → 16	17-19	20 22 23 24	

Current Limit of Flexible bronchoscopy – 4/5 th order bronchi

Flexible Bronchoscopy- Indications

- **Diagnostic**
  - Non massive hemoptysis
  - Stridor /Localized wheeze
  - Suspected TEF
  - Chest trauma
  - Pulmonary nodule/ mass
  - Mediastinal / hilar Lymphadenopathy
  - Pneumonia
    - Immunocompromised
    - Nosocomial
    - Non-resolving
  - Evaluation rejection

- **Therapeutic**
  - Central Airway Obstruction
    - Laser photoresection
    - Electrocautery
    - Argon plasma coagulation
    - Brachytherapy
    - Photodynamic therapy
  - FB removal
  - Balloon Dilatation
  - Pulmonary toilet
  - Endotracheal Intubation
  - Percutaneous dilatational tracheostomy
  - Metallic Stent placement

Flexible Bronchoscopy-Contraindications

- **Inspection**
  - Life-threatening arrhythmia
  - Refractory Hypoxemia
  - Inability to cooperate with procedure
  - Recent MI or unstable angina
- **Biopsy**
  - Serum creatinine >3
  - Platelets <50,000
  - Uncorrected coagulopathy
  - Pulmonary HTN
  - SVC syndrome

Rigid Bronchoscopy

Courtesy of Robert Garland RRT

Rigid Bronchoscopy

- **Indications**
  - FB removal
  - Hemoptysis
  - Central airway obstruction
    - Treatment
      - Benign/ Malignant
      - Laser, EC, Cryotherapy, APC, Dilatation, Microdebrider
  - **Stent placement**
    - Hybrid
    - Silicone

Rigid Bronchoscopy

- **Contraindication**
  - Unstable CV status
  - Refractory hypoxemia
  - Maxilo-facial trauma
  - Limited ROM of head and neck
  - C-spine instability
  - Inexperience