

Ischemic Mitral Regurgitation (IMR)

Part 1:

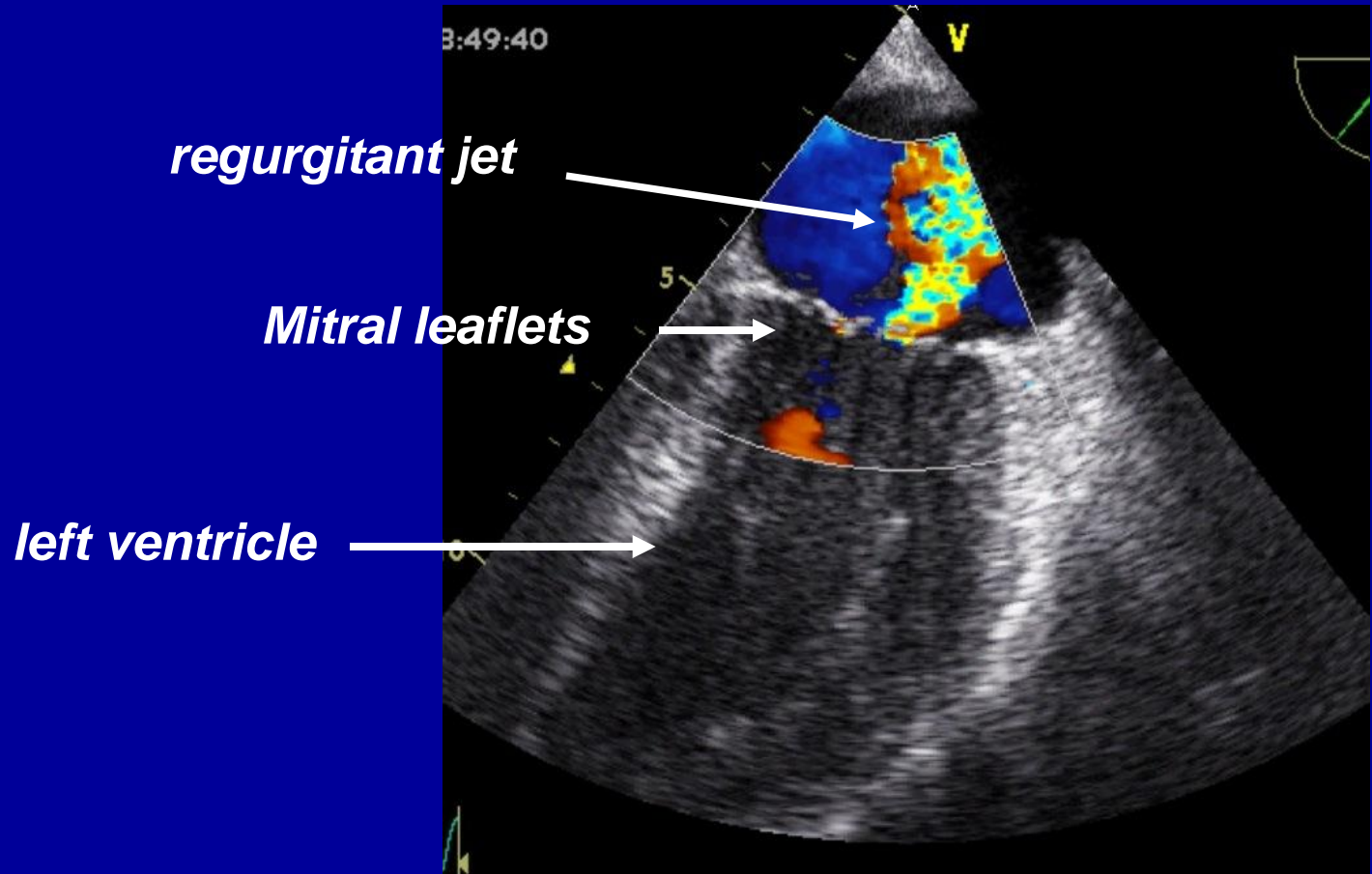
Terminology and General Considerations for Treatment

P. Kent Harman, M.D.

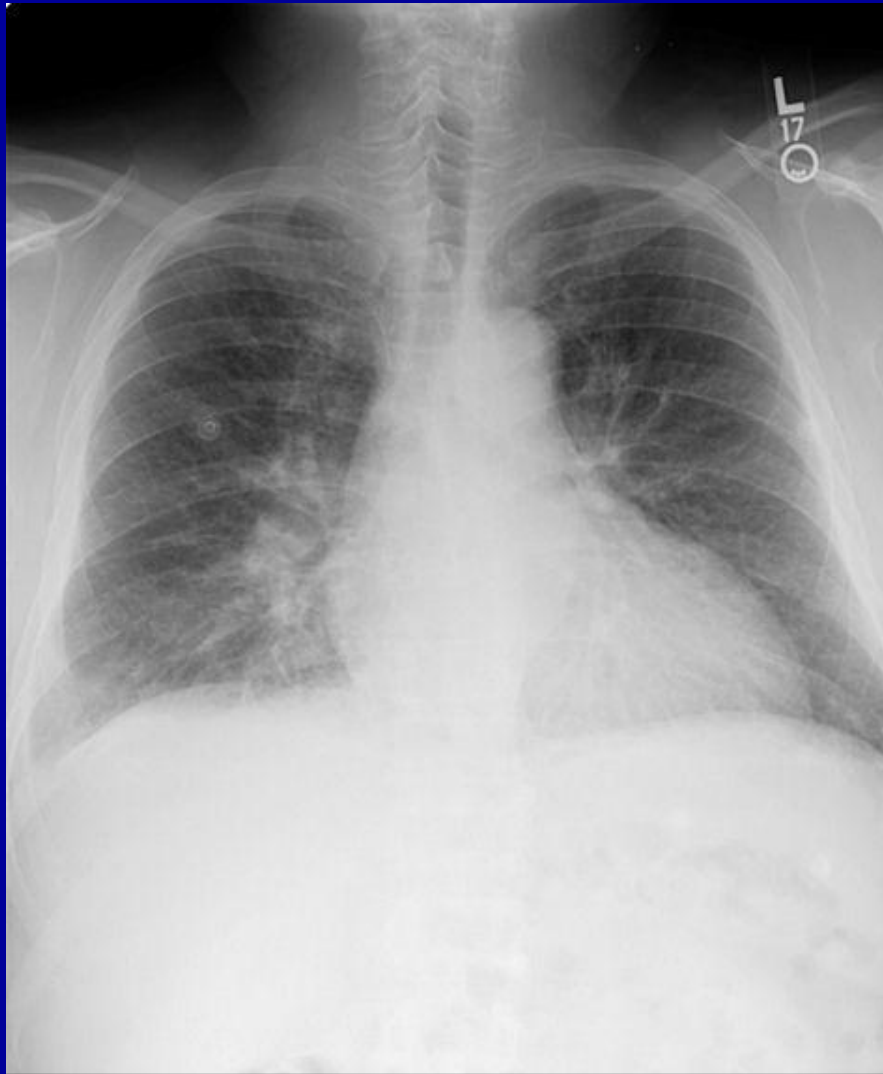***Division of Thoracic and Cardiovascular Surgery
University of Florida College of Medicine***



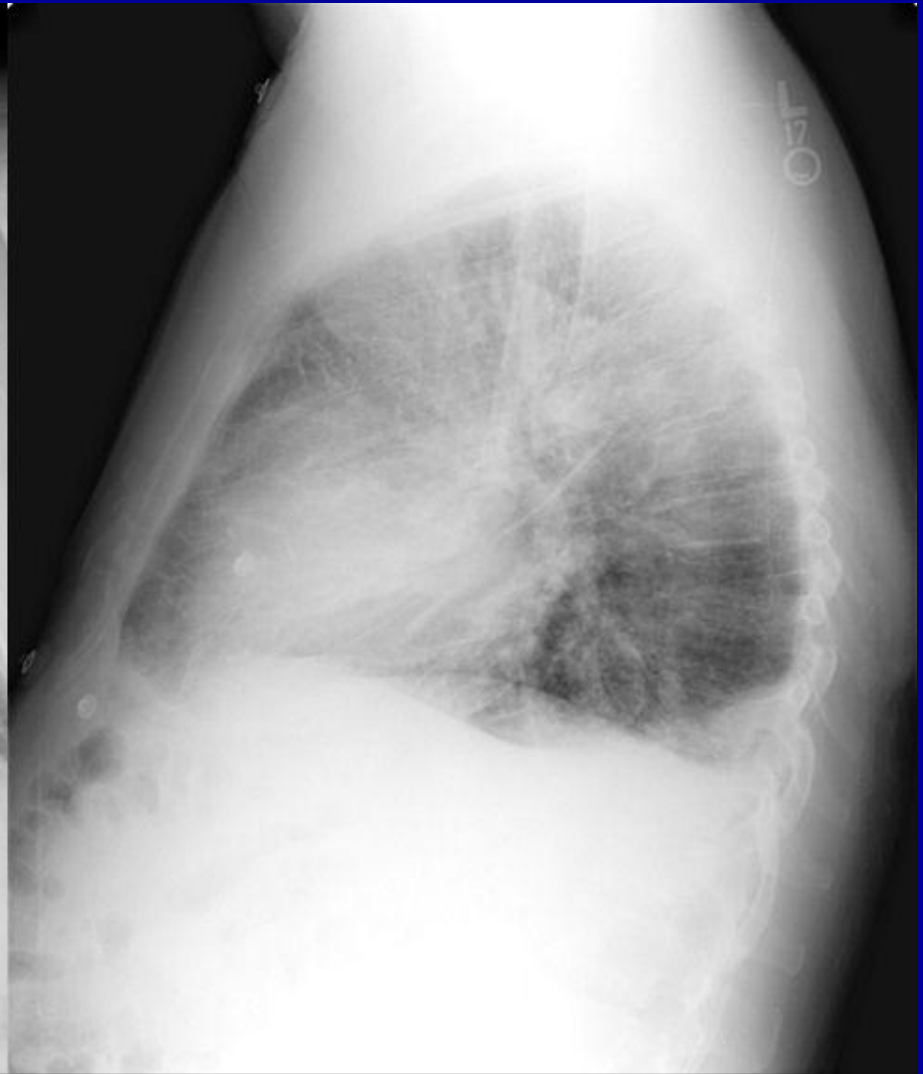
Enlarged LV and mitral regurgitation



Chronic dilated ischemic MR



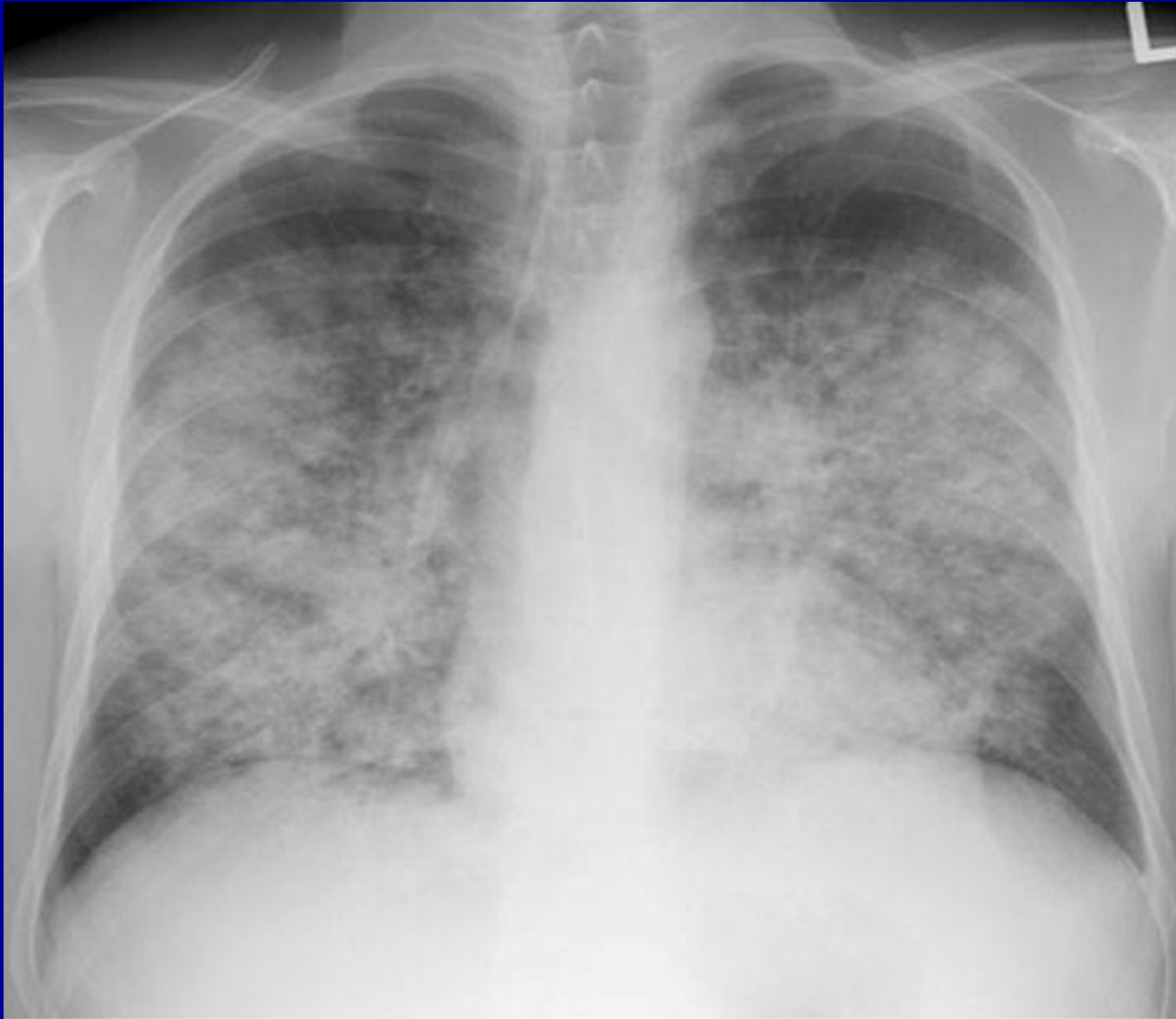Frontal



Lateral



Acute ischemic MR

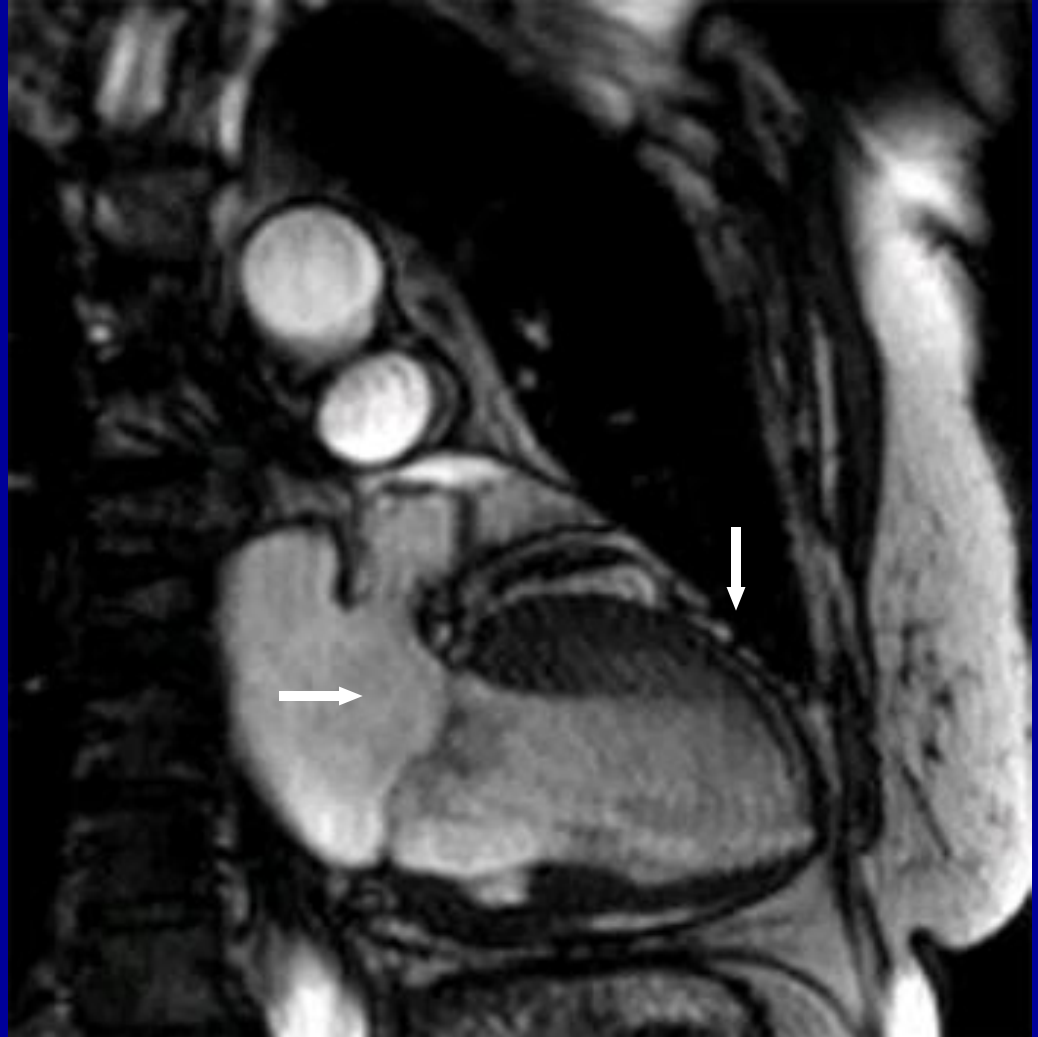


Fresh anteroseptal infarct

Parasternal view

1. Anterior wall akinesia

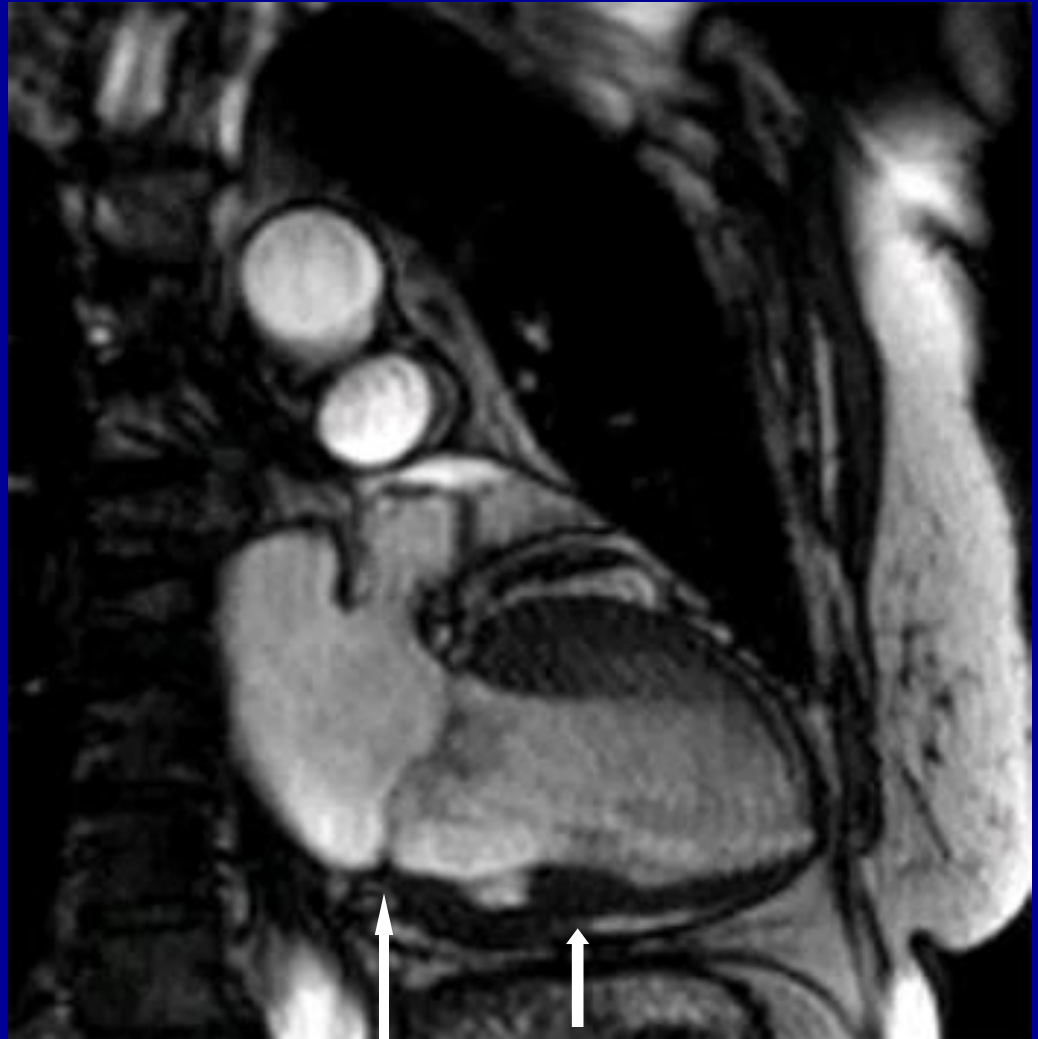
2. Central MR



Anterior infarct

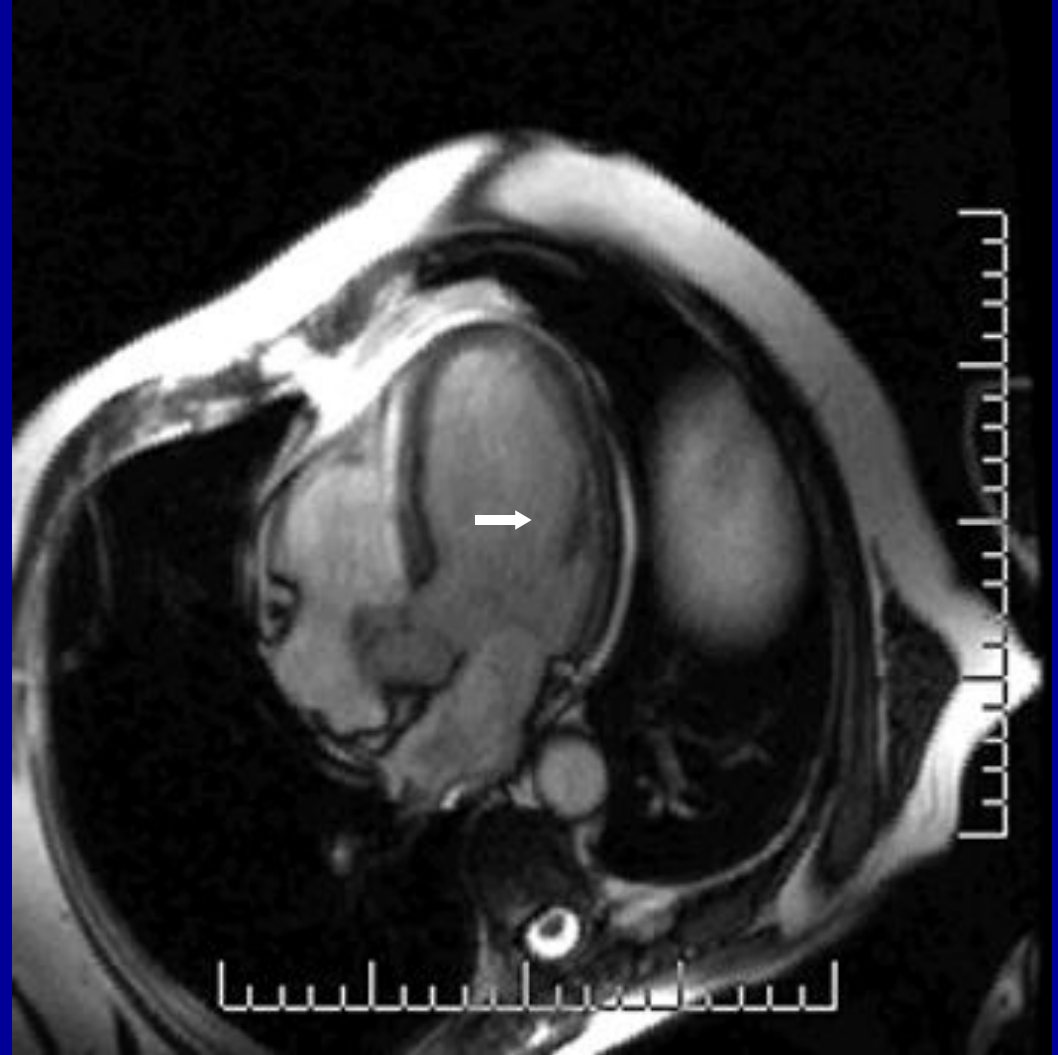
Parasternal view

- 1. Anterior wall akinesia*
- 2. Central MR*

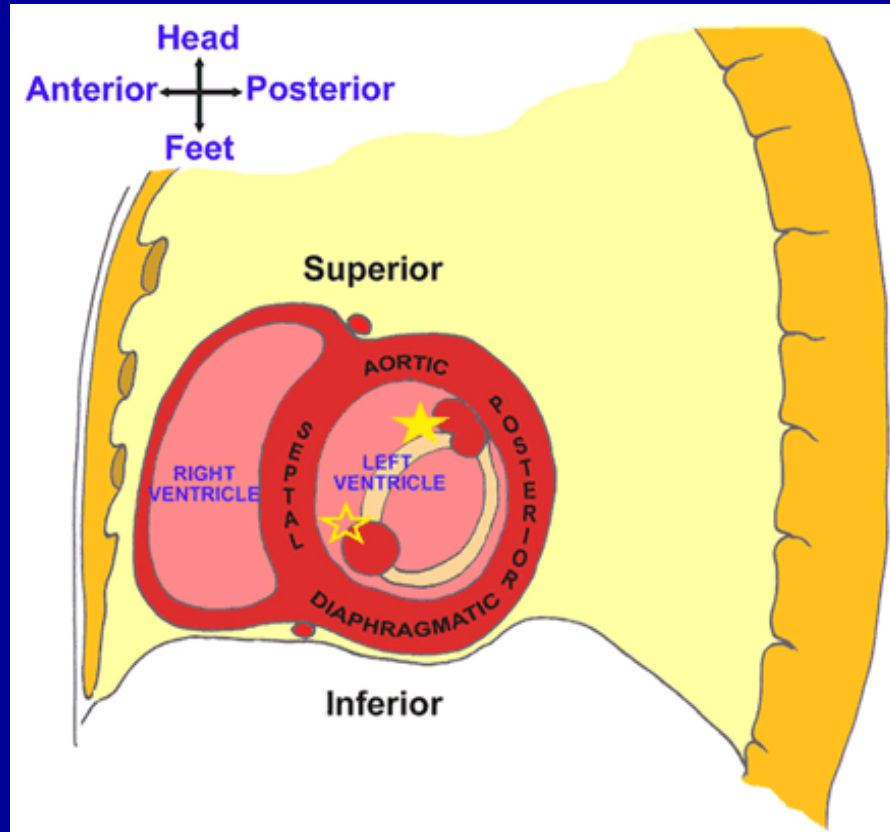


Anteroseptal infarct

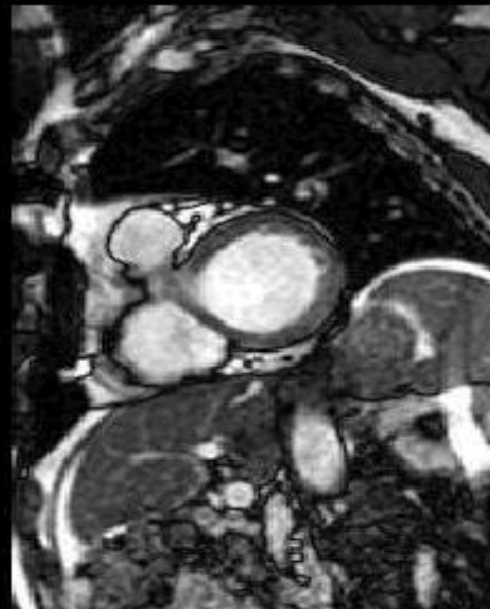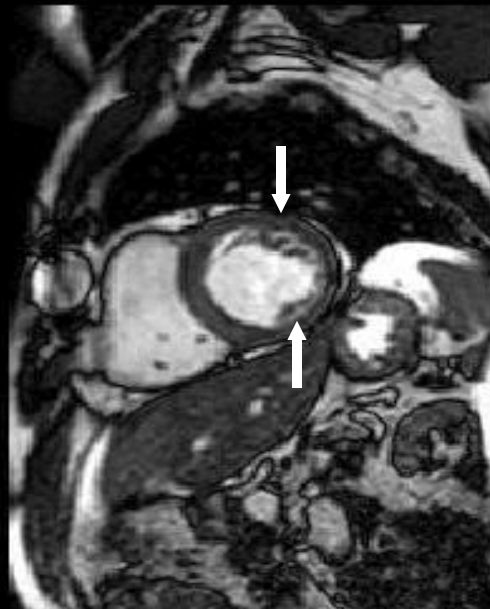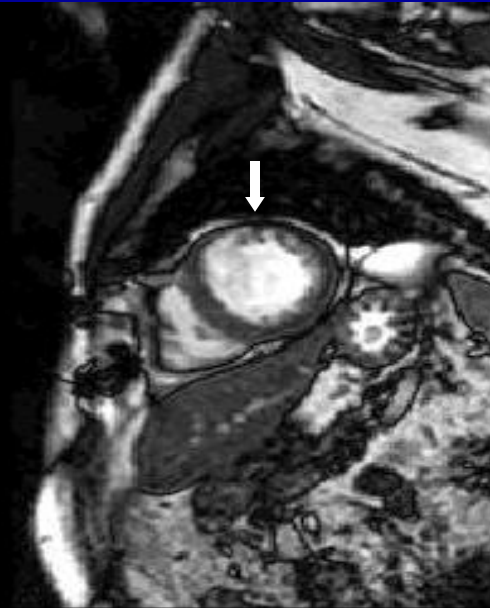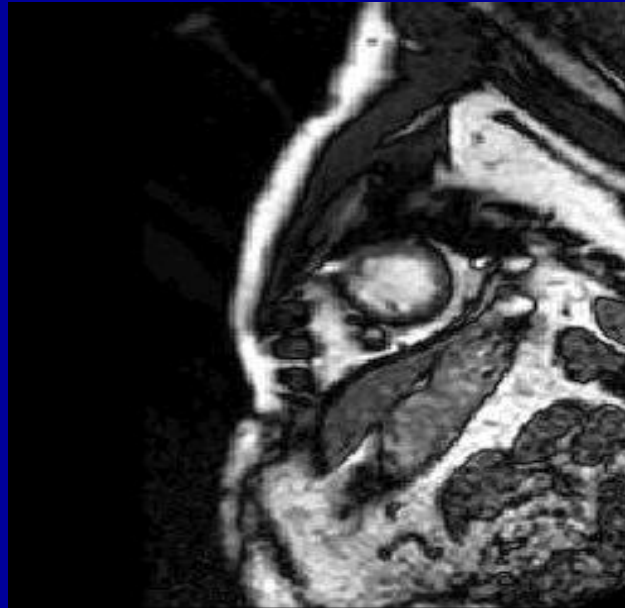
*Cardiac MRI -
4 chamber view*



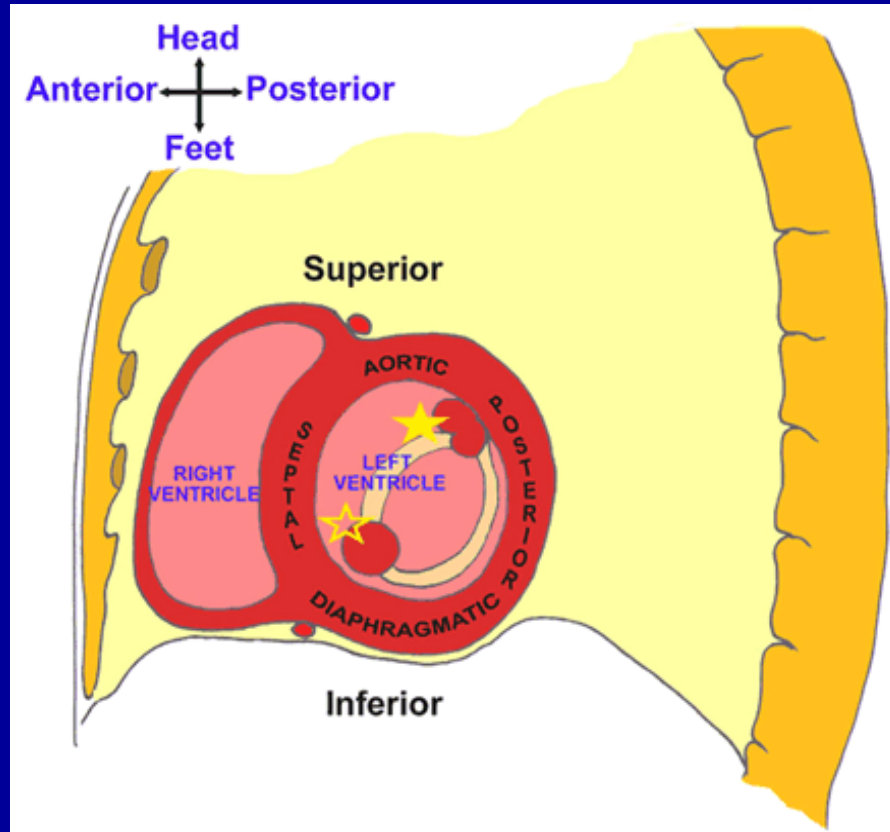
Mitral Subvalvar Anatomy



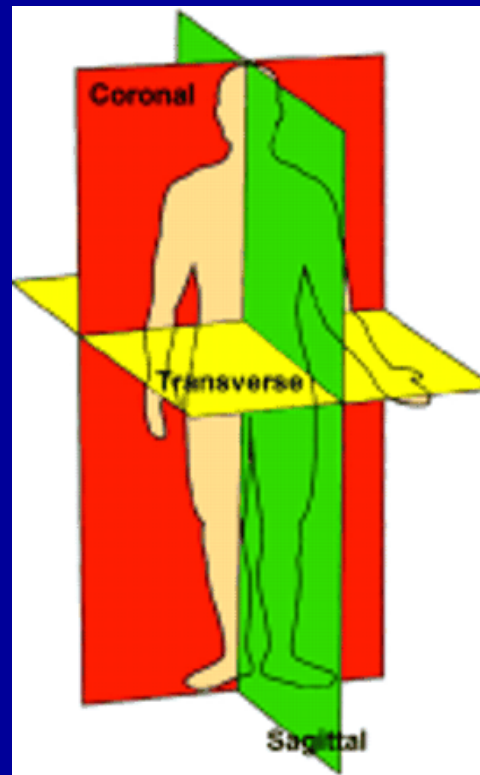
Cross-sectional view, Anterior MI



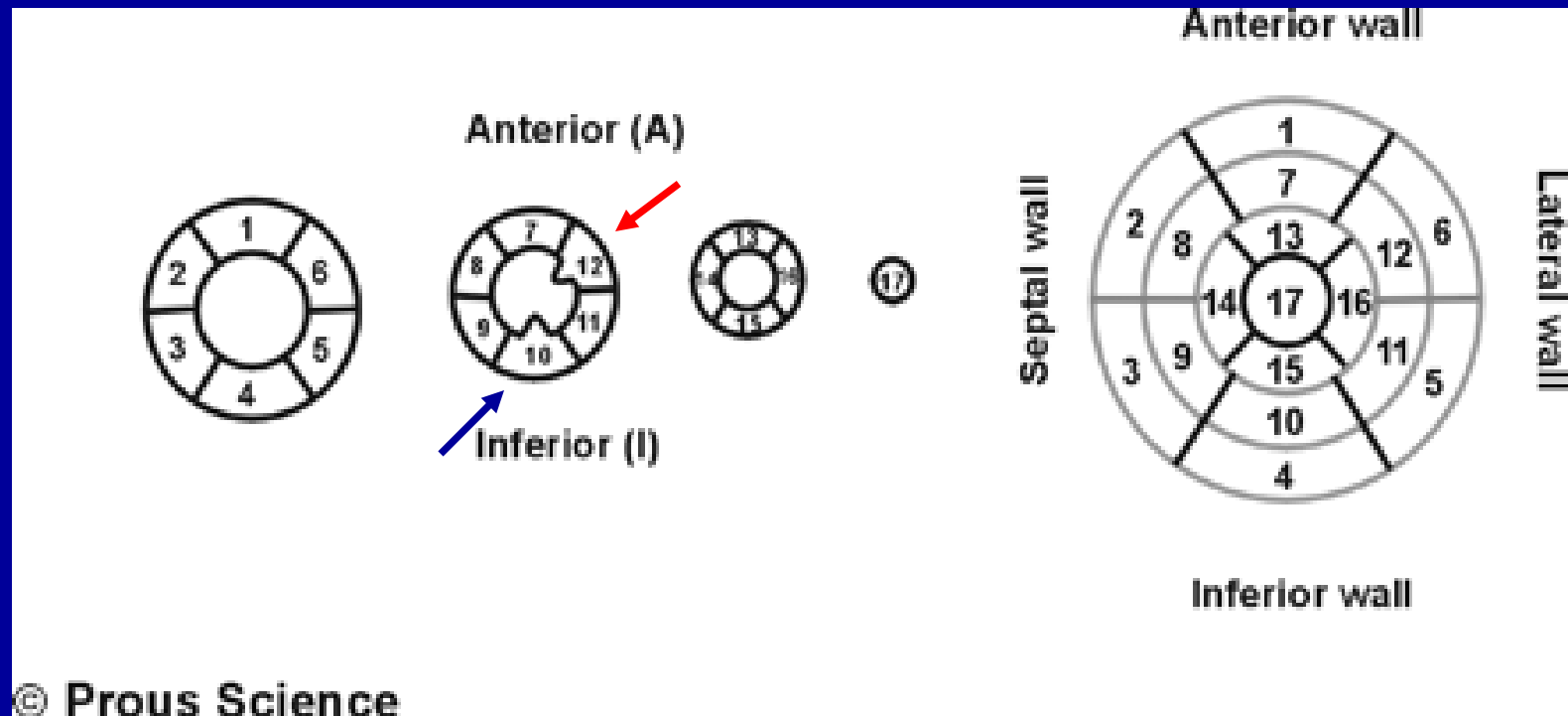
Mitral Subvalvar Anatomy



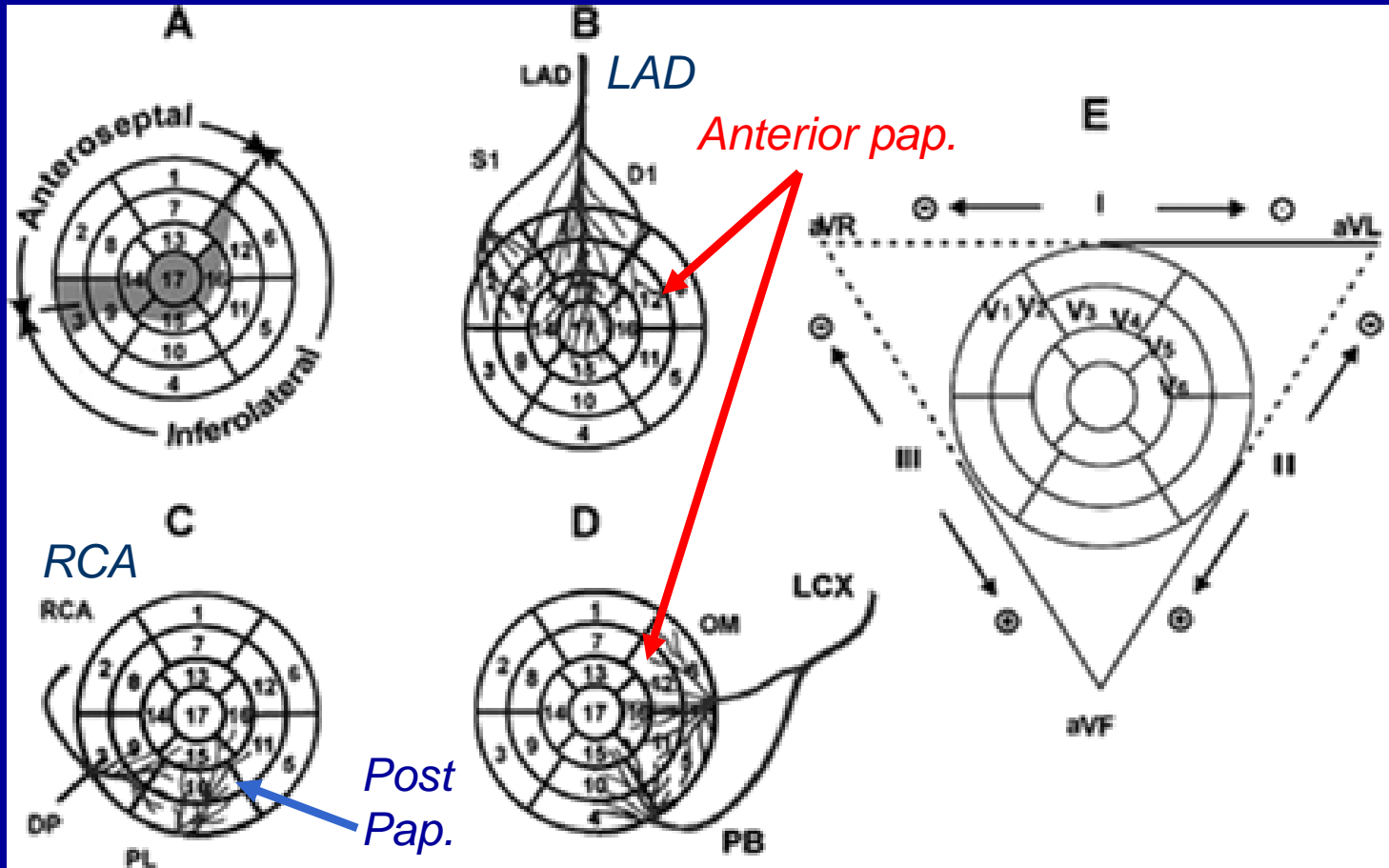
Three orthogonal planes



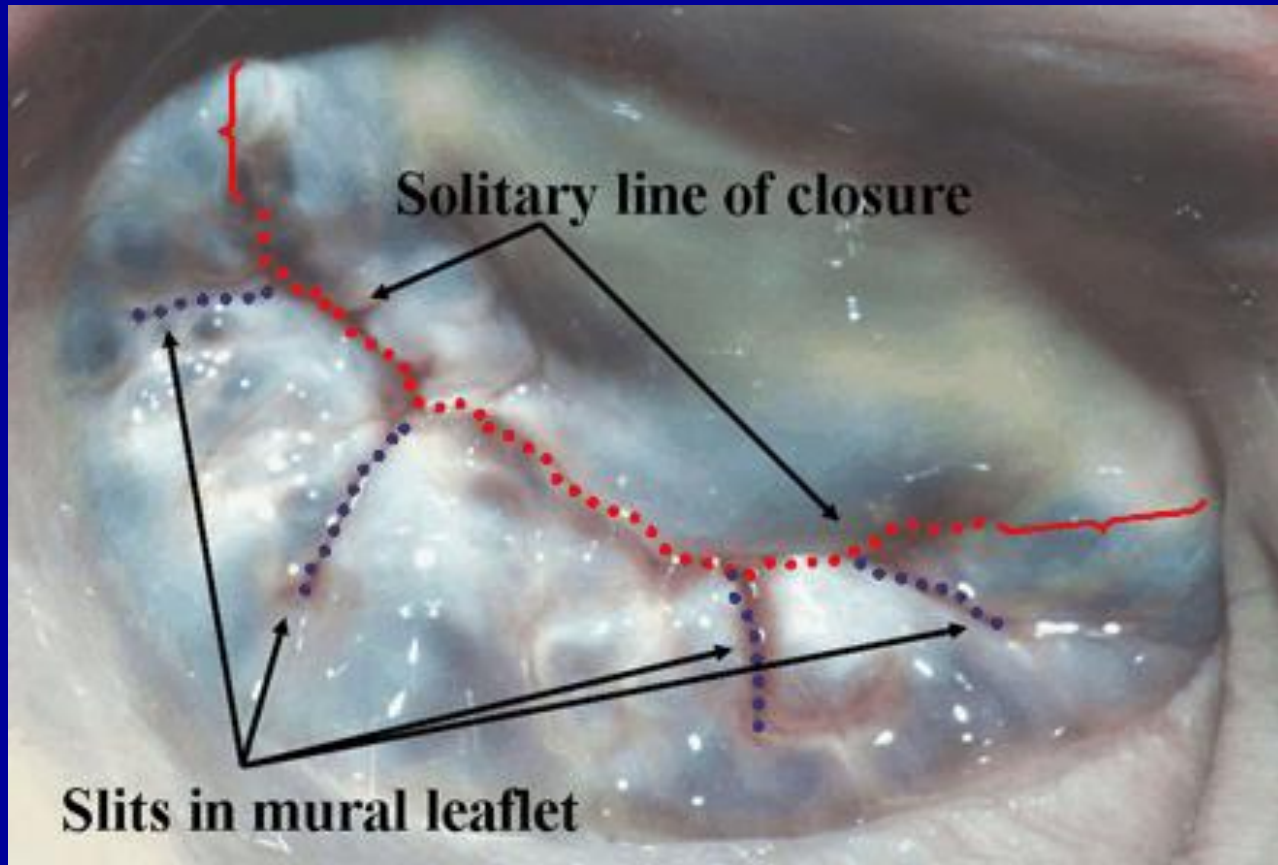
CMR LV Segments, Terminology



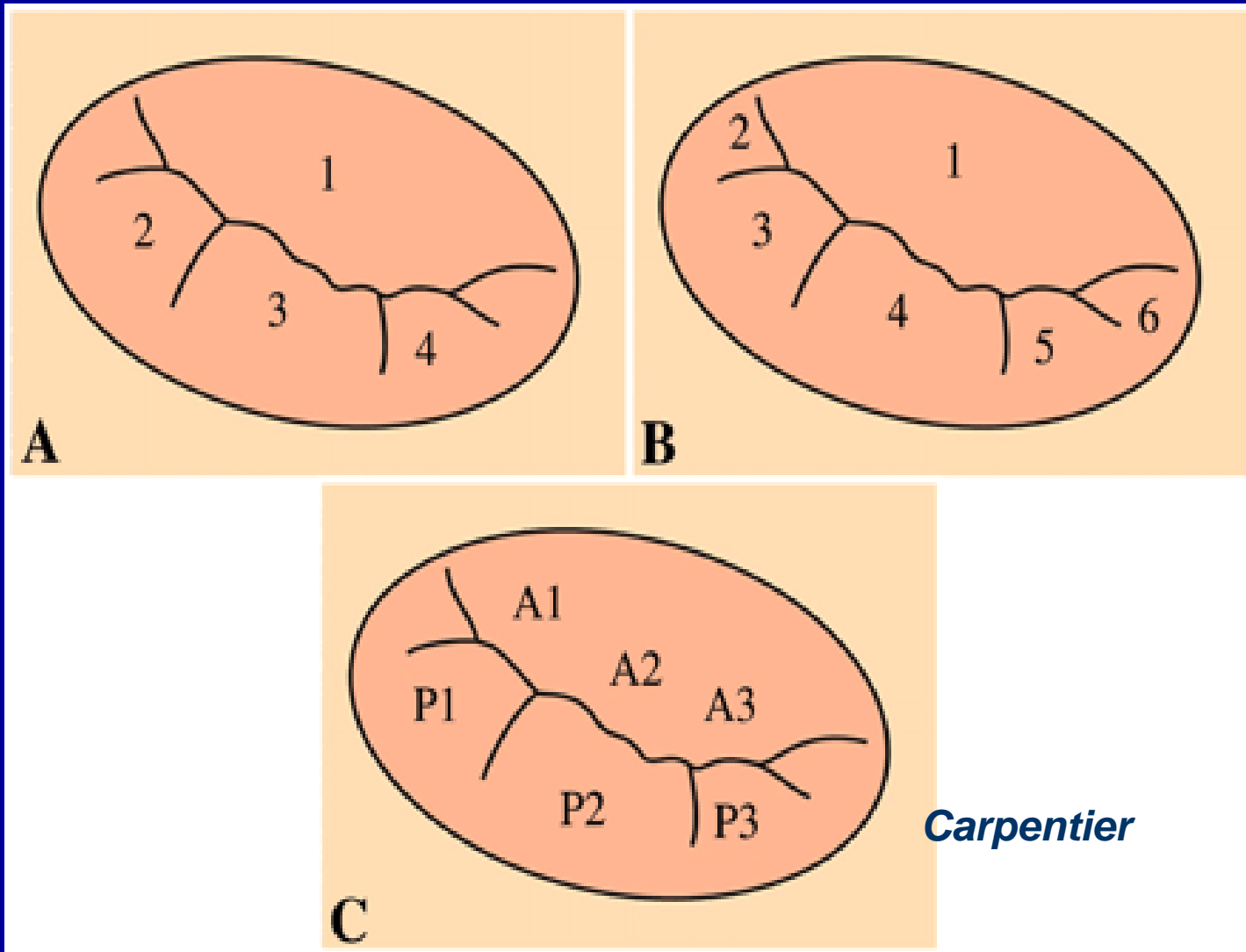
Papillary muscle blood supply



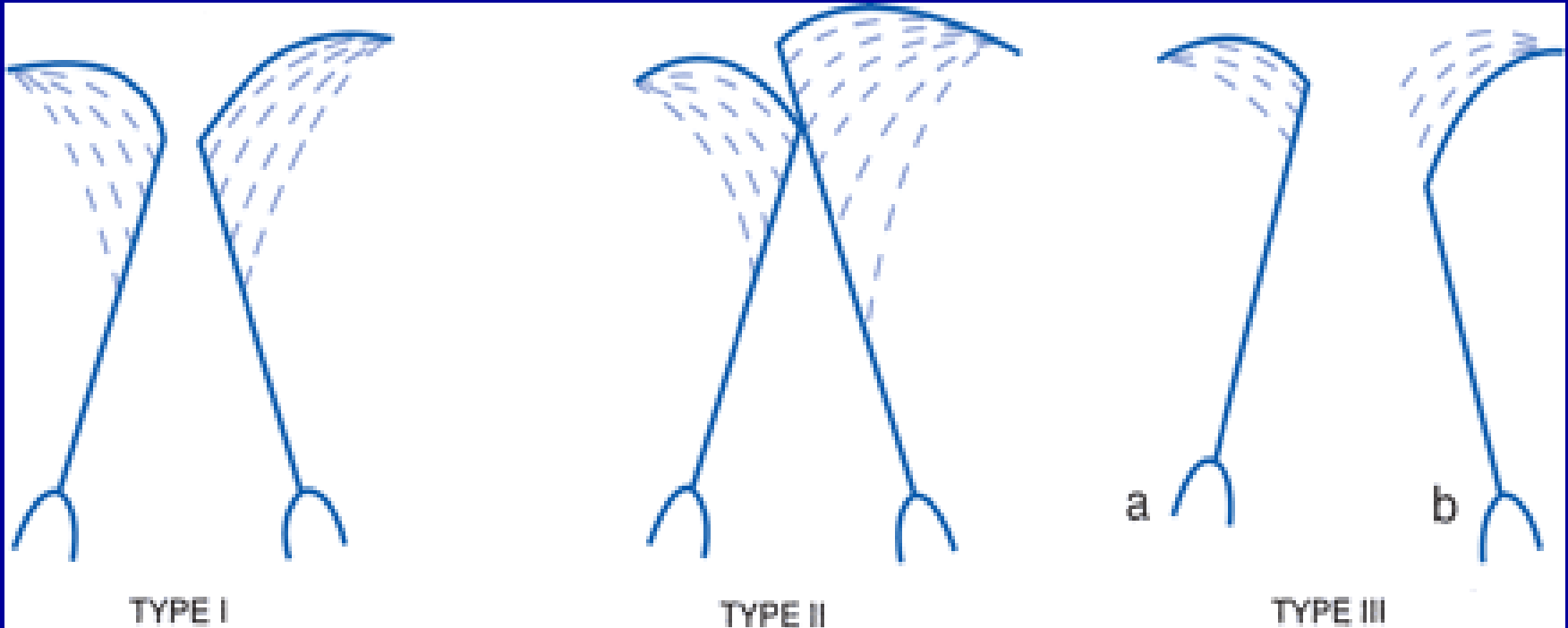
Mitral leaflets and zone of apposition



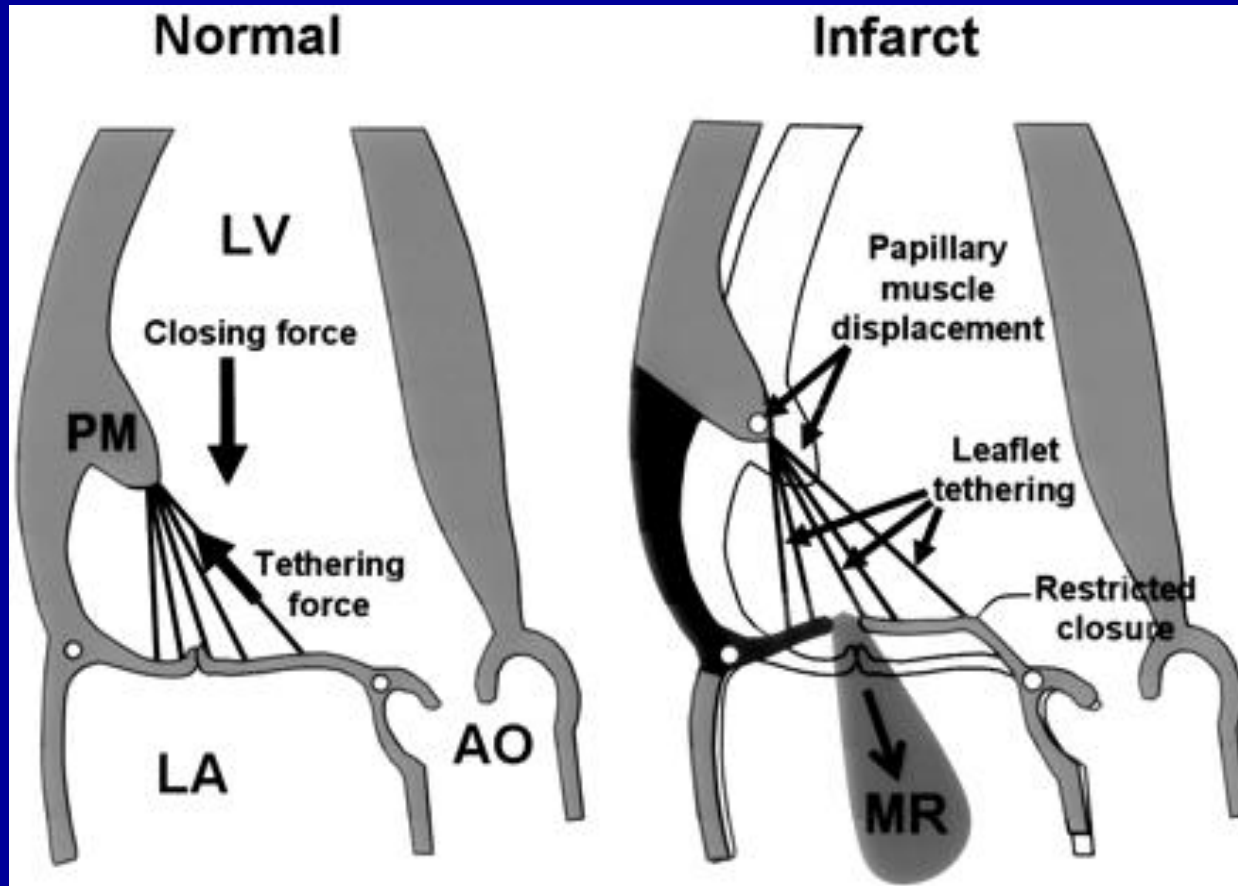
Leaflet Terminology



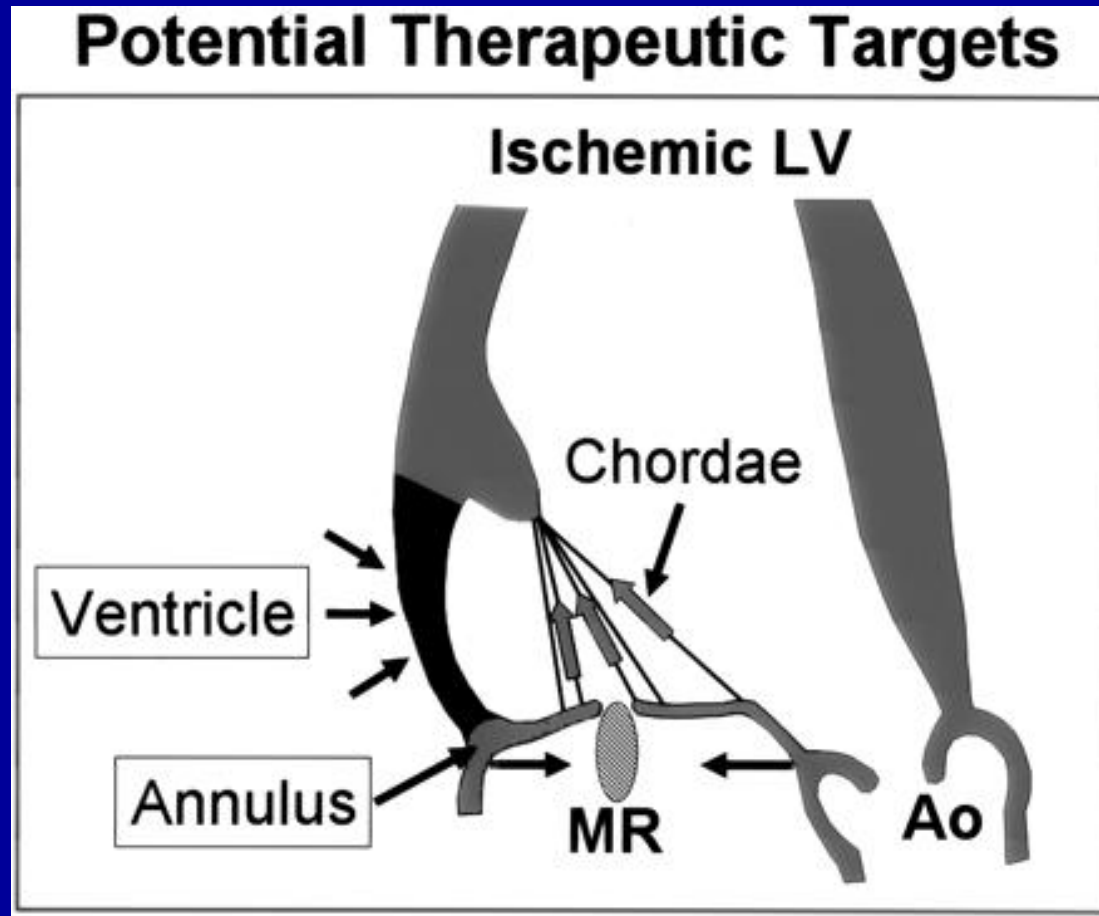
Carpentier's Classification



Infero-basal MI and papillary displacement



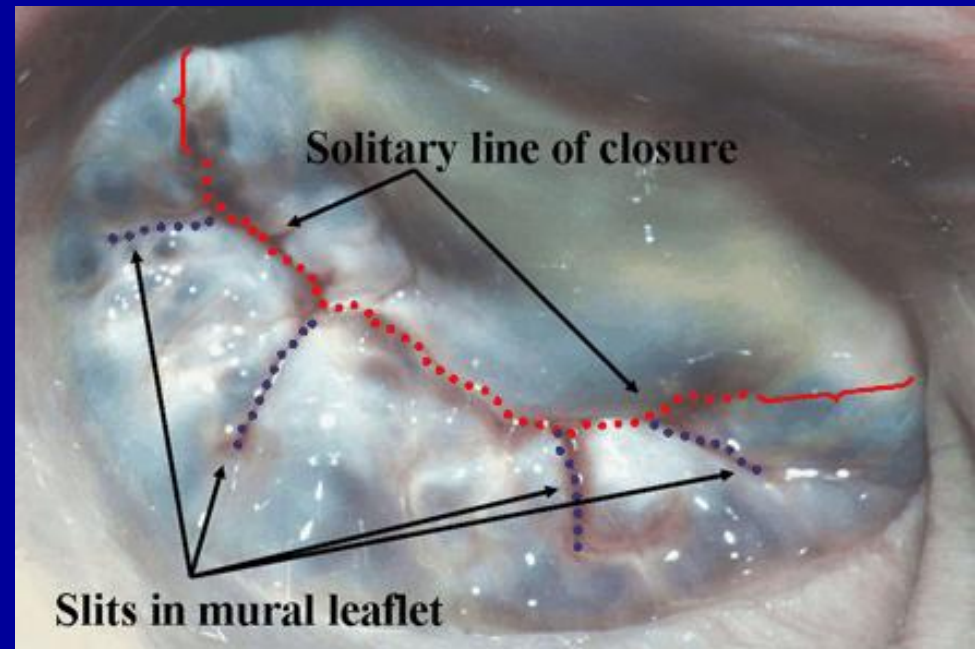
Anatomic considerations for repair



Characteristics of Ischemic MR

**Normal leaflets, but
abnormal connections to the heart involving the:**

- 1. annulus**
- 2. chordae**
- 3. papillary muscles, and**
- 4. ventricular wall.**



Potential Therapeutic Targets

- *Revascularization*
- *Surgical ventricular restoration*
- *Papillary muscle repositioning*
- *Chordal cutting*
- *Annular reshaping*
- *External support*



*Division of Thoracic and Cardiovascular Surgery
University of Florida College of Medicine
2008*